

Solitary Atypical Myocysticercosis in the Trapezius Muscle: A Case Report

GUNEET SINGH¹, VIRENDRA ATHAVALE², SIDDHARTH TIWARI³, KONDAPALLI SRI SAI TEJA SAMPATH⁴,
NAYANI NITHIN KUMAR⁵



ABSTRACT

One of the most dangerous parasitic infections found practically everywhere in the world is cysticercosis, which is also considered a neglected tropical disease. Cattle are the intermediate hosts in the life cycle of the parasite that causes cysticercosis, known as *Cysticerci*, which is the larval form of the beef tapeworm *Taenia saginata*. When raw or undercooked meat is consumed, human cysticercosis develops, turning the person into an unintentional intermediate host. In areas with inadequate sanitation, cysticercosis is endemic. Although human cysticercosis is becoming less common due to improved living and hygiene conditions, the primary locations of these cysts are in the skeletal muscles and subcutaneous tissues. Such cases are, however, sometimes observed. It is uncommon for a young male to exhibit involvement of the trapezius muscle. In this case report, we present an incidental diagnosis of myocysticercosis. The patient underwent radiological investigation, and surgical excision was successfully performed. We emphasise the importance of diagnostic work-up, management, and follow-up, as well as the need for a clinical suspicion of parasitic infestation in settings similar to ours for better management.

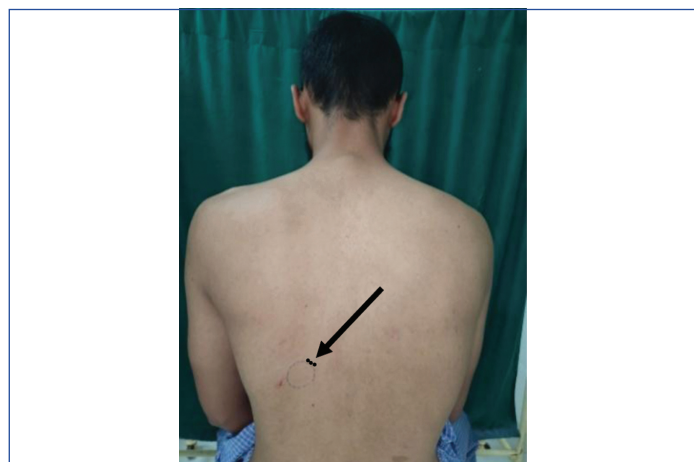
Keywords: Parasite, Scolex, Subcutaneous, *Taenia*

CASE REPORT

A 23-year-old Muslim male resident of Pune, Maharashtra, presented with complaints of a solitary swelling on his back for two years, which was initially 1×1 cm and had gradually progressed to a present size of approximately 2×2 cm. The patient denied any history of pain, discharge, local trauma, fever, or insect bite. There was no history of altered sensorium, irritability, or any other visible swelling elsewhere on the body. No history of similar complaints in the family was reported.

On clinical examination, a solitary swelling was noted on the left back, with normal skin over the swelling. The swelling was prominent when bending forward, and there was no evidence of a scar or sinuses.

On palpation, there was a solitary swelling measuring 2×2 cm with regular and well-defined borders. The swelling was mobile in all directions, nontender, firm in consistency, and there was no evidence of fluctuation. The skin over the swelling was pinchable, and the plane of the swelling was deep in the muscle [Table/Fig-1].

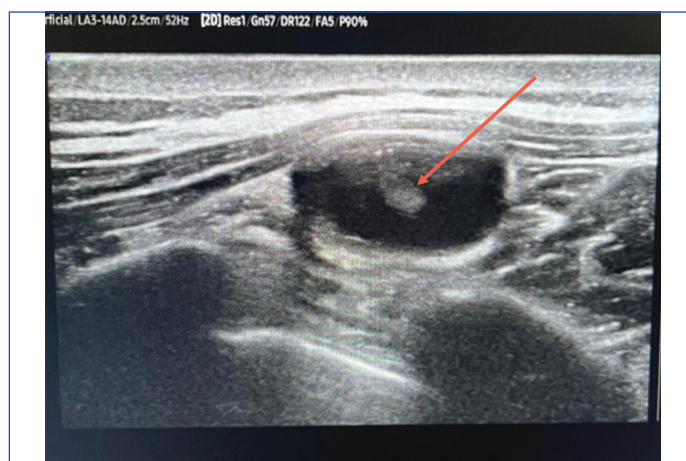


[Table/Fig-1]: Cyst over left back.

Differential diagnosis included subcutaneous lipoma, sebaceous cyst, and subcutaneous calcification.

On further radiological investigation, an ultrasonography using a high-frequency linear probe revealed a well-circumscribed oval anechoic cystic lesion measuring 7.7×13.3×22.7 mm (AP×TR×CC),

with slightly thickened oedematous walls (wall thickness 1.3 mm) in the intramuscular plane at the clinically indicated site in the left upper back region. An echogenic structure measuring 4×3.5 mm was noted projecting internally within the cystic cavity from the wall, likely a scolex [Table/Fig-2]. The rest of the visualised soft tissues appeared normal and no evidence of significant fluid in the visualised muscles and tendons was seen. The underlying bony cortical outlines appeared grossly normal.



[Table/Fig-2]: Showing echogenic structure projecting internally.

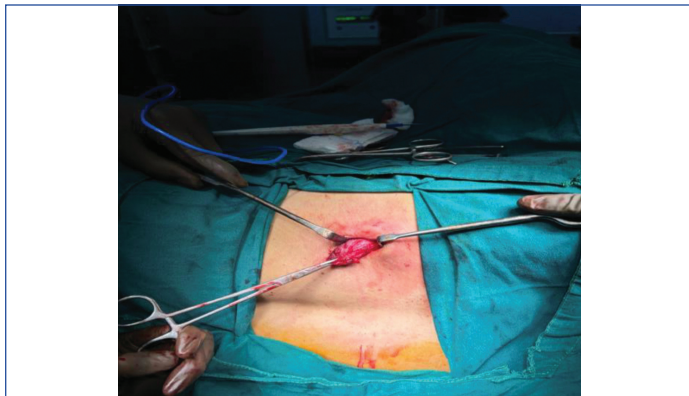Upon further questioning, the patient revealed a history of regular beef consumption. There was no history of itching, seizures, blurry vision, or exposure to animals or pets. Therefore, we considered the possibility of myocysticercosis. To rule out a parasitic infection and disseminated spread, routine blood investigations were performed [Table/Fig-3].

- IgG for *T. saginata* was found to be positive.
- Stool routine microscopy did not reveal any ova or proglottids.
- A CT scan of the brain revealed no abnormalities.

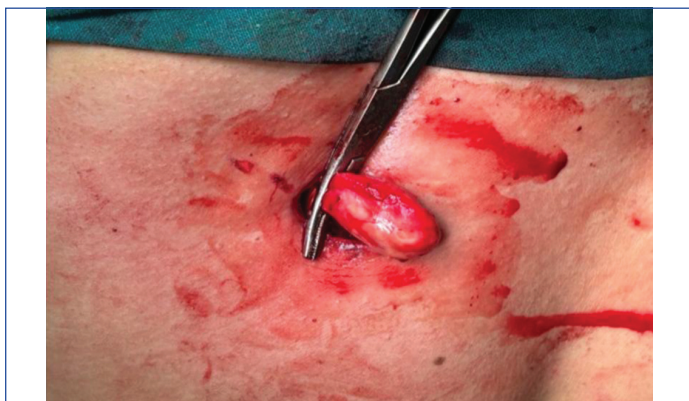During the surgical excision of the swelling, the specimen was cut open, revealing serous fluid, which was sent for culture and sensitivity; this revealed no growth. Additionally, evidence of a solitary glistening white scolex was observed [Table/Fig-4-6].

Blood investigation	Value	Reference range
Hb	11 g/dL	13.2-16.5 g/dL
TLC	8,800 u/L	4000-11000 u/L
Platelet count	449,000 u/L	150000-410000 u/L
Neutrophils	40%	40-80%
Lymphocytes	68%	20-60%
Eosinophils	2%	1-6%

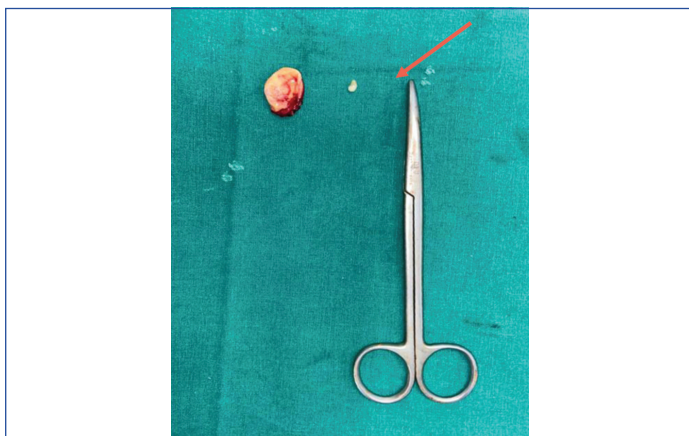
[Table/Fig-3]: Blood test result.



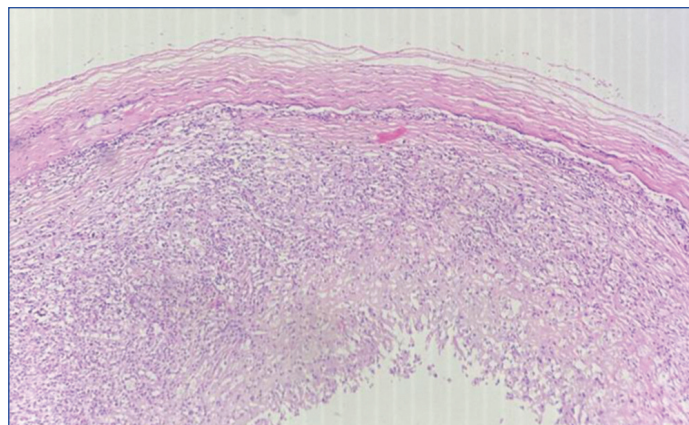
[Table/Fig-4]: Intraoperative image of cyst in total.



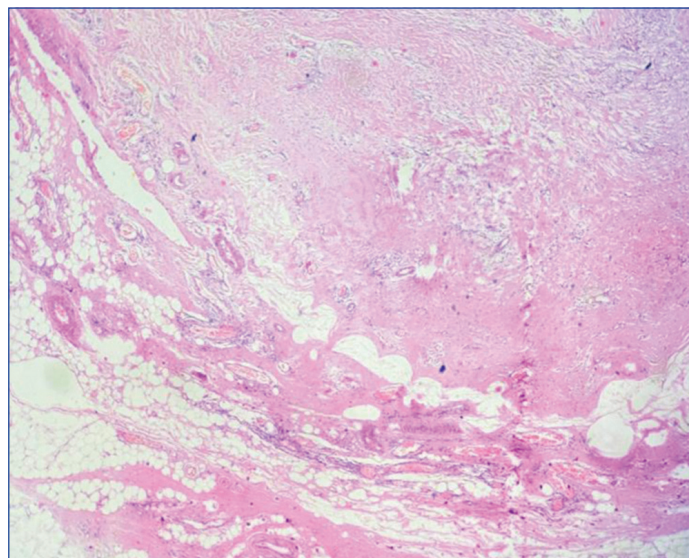
[Table/Fig-5]: Intraoperative image of cyst deep to muscle.



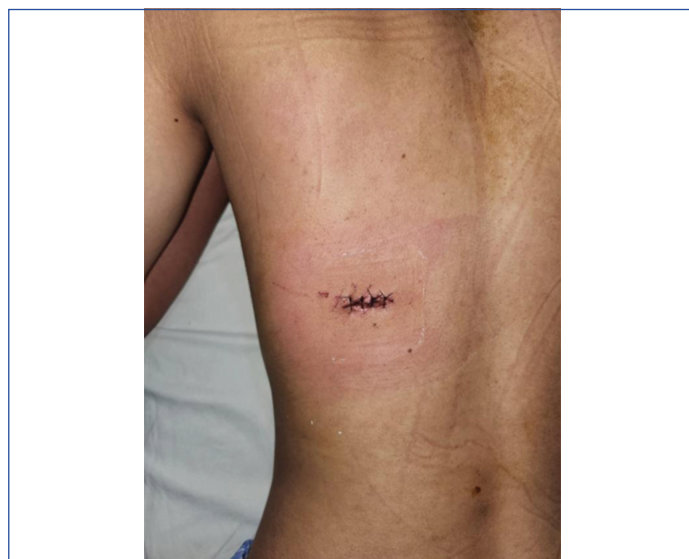[Table/Fig-6]: Excised cyst wall with scolex.



[Table/Fig-7]: 100X, H&E stain showing cyst wall with various lymphoid cells.



[Table/Fig-8]: 100x, H&E stain showing congested blood vessels with eosinophils.



[Table/Fig-9]: Suture line image.

The cyst wall and scolex were sent for histopathological examination, which revealed a fibro-collagenous cyst wall lined by aggregates of foamy histiocytes, neutrophils, lymphocytes, plasma cells, multinucleated giant cells, and occasional eosinophils, surrounded by congested blood vessels. This is suggestive of a cyst wall with chronic inflammation [Table/Fig-7,8].

The patient was treated with Albendazole 400 mg twice daily for 14 days and Praziquantel 300 mg three times daily for 14 days. Upon regular follow-up, the suture line was found to be healthy, and the patient did not develop any complications and remained compliant with the therapy [Table/Fig-9].

DISCUSSION

Taeniasis is an intestinal infection caused by adult tapeworms. Three parasite species cause taeniasis in humans: *Taenia solium* (pork tapeworm), *Taenia saginata* (beef tapeworm), and *Taenia asiatica* (a species phylogenetically closely related to *T. saginata*) [1]. The human definitive host gets infected with *T. saginata* and *T. solium* by consuming undercooked meat from the parasites' respective intermediate hosts (*T. saginata*: cattle; *T. solium*: pigs), which harbor the infective larval stage of the parasite (cysticerci) [2,3].

Although *Taenia* has a worldwide distribution, its occurrence is more common in low-income countries. A substantial prevalence

of *T. saginata*, considered the most common zoonotic tapeworm, has been reported throughout East, Southeast, and South Asia due to a lack of adequate sanitation, food safety measures, and health education standards [4].

Intramuscular cysticercosis has been reported mainly in cases with the disseminated form of the disease [5-9]. Three different clinical manifestations have been described: the myalgic type, the mass-like or pseudo-tumour type, and the rare pseudo-hypertrophic type [8-10]. Our patient presented with a clinically solitary, mass-like abnormality. Symptoms such as redness, swelling, or pain may be observed after the death or degeneration of the parasite, leading to leakage of antigens and a cellular response from the body [11].

When the parasites reach an organ, they encyst and remain as viable cysts. This phase may last for years and is often clinically silent because viable cysts are protected by the blood-brain barrier and are successfully sequestered from host immune responses. There is one report indicating that a cysticercus survived silently for more than 10 years [12].

T. saginata is almost completely harmless to humans. Most patients infected with *T. saginata* are asymptomatic or have minimal symptoms. *T. saginata* has been linked to intestinal perforation and oral ejection, reaching lengths of up to three meters [13].

The diagnosis of intramuscular cysticercosis is often delayed, as isolated intramuscular involvement of cysticercosis is uncommon. High-resolution ultrasound is the most accurate method to diagnose intramuscular cysticercosis since it is quick, easy, and inexpensive. The sonographic patterns of muscular cysticercosis are divided into four types: first degree, uneven, irregular, and calcified.

The first form is a cysticercus cyst, which is surrounded by an inflammatory mass caused by the larva's demise. The second type of cyst is irregular, with very little fluid on one side, indicating fluid leakage. This cyst does not contain the eccentric echogenic protrusion from the wall caused by the scolex. This appearance could be the result of the scolex escaping from the cyst or the cyst partially collapsing. The third form features a large irregular collection of exudative fluid within the muscle, as well as the usual cysticercus cyst containing the scolex, which is located eccentrically within the fluid collection. This could be related to a prolonged inflammatory response around the cyst. This appearance resembles an intramuscular abscess. The diagnostic hallmark in all three types of presentations is the cysticercus itself, which appears as an oval or round well-defined cystic lesion with an eccentric echogenic scolex. The fourth type consists of calcified cysts, which appear as numerous elliptical calcifications in soft tissue [14]. In our patient, it was the third form of cyst, characterised by fluid collection and a scolex within the cyst.

Magnetic Resonance Imaging (MRI) is the most accurate method for diagnosing intramuscular cysticercosis since it can detect live scolex, cysts, and degenerating cysts. In all cases, there is oedema to varying degrees, with fluid-filled lesions without peripheral enhancement seen in the early stages and peripheral rim augmentation and perilesional oedema observed later [15].

Histological examination has been described in stages:

- **Colloidal stage:** The first stage of involution of cysticerci; a turbid, viscous fluid replaces the transparent vesicular fluid, and the scolex shows signs of hyaline degeneration.
- **Granular stage:** The cysticercus is no longer viable; the cyst wall thickens, and the scolex is transformed into coarse mineralised granules. A host inflammatory reaction is usually not present if the larva is viable. Finally, a granulomatous reaction develops, characterised by histiocytes, epithelioid cells, and foreign body giant cells, leading to fibrosis of the

supporting stroma and calcification of the parasitic debris [16]. In our case, the cyst was in the granulomatous stage.

Surgical removal is indicated for localised lesions that cause obvious symptoms. Medical treatment with praziquantel or albendazole, which are anti-helminthics, has been recommended for neurocysticercosis and subcutaneous cysticercosis [17,18]. We have successfully managed the patient with surgical excision of the swelling and conservatively with albendazole and praziquantel. Steroids may also be used in cases where an inflammatory reaction is present in the host [19]. In our case report, there was no evidence of a host inflammatory reaction; hence, no steroids were used in the management.

In a previous case similar to ours, a solitary intramuscular cysticercosis was diagnosed in a 47-year-old male who presented with a history of pain while chewing in the right masseter muscle. He was diagnosed with cysticercosis involving the right masseter muscle. The patient was prescribed Tab Albendazole 400 mg (BD) for four weeks and Tab Prednisolone 10 mg (TDS) for two weeks, leading to the lesion's complete resolution [20].

CONCLUSION(S)

The possibility of intramuscular cysticercosis should be kept in differential in endemic regions as in like ours, whenever a patient presents with a nodule or swelling over the body. Only symptomatic cysts require treatment. Both surgery and medical management have been found to yield good results and thus the treatment may be individualised.

REFERENCES

- [1] Eom KS, Rim HJ, Jeon HK. *Taenia asiatica*: Historical overview of taeniasis and cysticercosis with molecular characterization. *Adv Parasitol*. 2020;108:133-73.
- [2] World Health Organization. Taeniasis/cysticercosis. 2020. Accessed April 10, 2021. Available from: <https://www.who.int/news-room/fact-sheets/detail/taeniasis-cysticercosis>.
- [3] United States Centers for Disease Control and Prevention. Taeniasis. 2017. Accessed March 28, 2021. Available from: <https://www.cdc.gov/dpdx/taeniasis/index.html>.
- [4] Eichenberger RM, Thomas LF, Gabriël S, Bobić B, Devleeschauwer B, Robertson LJ, et al. Epidemiology of *Taenia saginata* taeniasis/cysticercosis: A systematic review of the distribution in East, Southeast and South Asia. *Parasit Vectors*. 2020;13(1):234.
- [5] Bothale KA, Mahore SD, Maimoon SA. A rare case of disseminated cysticercosis. *Trop Parasitol*. 2012;2(2):138-41. Doi: 10.4103/2229-5070.105183.
- [6] Banu A, Veena N. A rare case of disseminated cysticercosis: Case report and review of literature. *Indian J Med Microbiol*. 2011;29(2):180-83. Doi: 10.4103/0255-0857.81787.
- [7] Bhalla A, Sood A, Sachdev A, Varma V. Disseminated cysticercosis: A case report and review of the literature. *J Med Case Rep*. 2008;2;137. Doi: 10.1186/1752-1947-2-137.
- [8] Asrani A, Morani A. Primary sonographic diagnosis of disseminated muscular cysticercosis. *J Ultrasound Med*. 2004;23(9):1245-48.
- [9] Bandyopadhyay D, Sen S. Disseminated cysticercosis with huge muscle hypertrophy. *Indian J Dermatol*. 2009;54(1):49-51. Doi: 10.4103/0019-5154.48987.
- [10] Singal R, Mittal A, Gupta S, Gupta R, Sahu P, Gupta A. Intramuscular cysticercosis diagnosed on ultrasonography in thigh: A rare case report. *N Am J Med Sci*. 2010;2(3):162-64.
- [11] Kanhere S, Bhagat M, Phadke V, George R. Isolated intramuscular cysticercosis: A case report. *Malays J Med Sci*. 2015;22(2):65-68. PMID: 26023298; PMCID: PMC4438095.
- [12] Ito A, Nakao M, Ito Y, Yuzawa I, Morishima H, Kawano N, et al. Neurocysticercosis case with a single cyst in the brain showing dramatic drop in specific antibody titers within 1 year after curative surgical resection. *Parasitol Int*. 1999;48(1):95-99.
- [13] Dbouk S, Bazzi N, Mcheimeche H, Farhat MR, Alameh A, Rakka M. Stomach perforation and oral expulsion of *Taenia saginata*. *Am J Case Rep*. 2021;22:e928355.
- [14] Meena D, Gupta M, Jain VK, Arya RK. Isolated intramuscular cysticercosis: Clinicopathological features, diagnosis and management- A review. *J Clin Orthop Trauma*. 2016;7(Suppl 2):243-49. Epub 2016 Jun 30. Doi: 10.1016/j.jcot.2016.06.016. PMID: 28053392; PMCID: PMC5197059.
- [15] Gaur S, Parihar PS, Nimodia D. Two case reports of isolated intramuscular cysticercosis: An uncommon pediatric pseudotumor. *Cureus*. 2024;16(8):e68206. Doi: 10.7759/cureus.68206. PMID: 39347323; PMCID: PMC11439477.
- [16] Pathologyoutlines.com. 2025 [cited 2025 Feb 23]. Available from: <https://www.pathologyoutlines.com/topic/skinneoplasmsneoplasms/neurocysticercosis.html>.
- [17] Mittal A, Das D, Iyer N, Nagaraj J, Gupta M. Masseter cysticercosis- A rare case diagnosed on ultrasound. *Dent Maxillofac Radiology*. 2008;37(2):113-16.
- [18] Sidhu R, Nada R, Palta A, Mohan H, Suri S. Maxillofacial cysticercosis: Uncommon appearance of a common disease. *J Ultrasound Med*. 2002;21(2):199-202.

[19] Sharma S, Baghel A, Singh S, Verma M. Isolated intramuscular cysticercosis masquerading as tumor: Case report and review of literature. J Bone Joint Dis. 2023;38(2):204-07. Doi: 10.4103/jb.jd.jb.jd_25_23.

[20] Kiran B, Mehta S, Chaudhary R, Breh R. Cysticercosis involving the masseter muscle: A rare anatomical location. Advances in Oral and Maxillofacial Surgery. 2023;11:100434. Doi: 10.1016/j.adoms.2023.100434.

PARTICULARS OF CONTRIBUTORS:

1. Resident, Department of General Surgery, Dr. D. Y. Patil Medical College and Hospital and Research Centre, Pune, Maharashtra, India.
2. Professor, Department of General Surgery, Dr. D. Y. Patil Medical College and Hospital and Research Centre, Pune, Maharashtra, India.
3. Resident, Department of General Surgery, Dr. D. Y. Patil Medical College and Hospital and Research Centre, Pune, Maharashtra, India.
4. Resident, Department of General Surgery, Dr. D. Y. Patil Medical College and Hospital and Research Centre, Pune, Maharashtra, India.
5. Resident, Department of General Surgery, Dr. D. Y. Patil Medical College and Hospital and Research Centre, Pune, Maharashtra, India.

NAME, ADDRESS, E-MAIL ID OF THE CORRESPONDING AUTHOR:

Virendra Athavale,
Professor, Department of General Surgery, Dr. D. Y. Patil Medical College and Hospital and Research Centre, Pune-411018, Maharashtra, India.
E-mail: vsathavale@gmail.com

PLAGIARISM CHECKING METHODS: [Jain H et al.]

- Plagiarism X-checker: Dec 20, 2024
- Manual Googling: Mar 20, 2025
- iThenticate Software: Mar 22, 2025 (20%)

ETYMOLOGY: Author Origin

EMENDATIONS: 7

AUTHOR DECLARATION:

- Financial or Other Competing Interests: None
- Was informed consent obtained from the subjects involved in the study? Yes
- For any images presented appropriate consent has been obtained from the subjects. Yes

Date of Submission: Dec 18, 2024

Date of Peer Review: Feb 07, 2025

Date of Acceptance: Mar 25, 2025

Date of Publishing: Apr 01, 2025